

The nails have several important uses, which are easily appreciable when the nails are absent or they lose their function. The most evident use of fingernails is to be an ornament of the hand, but we must not underestimate other important functions, such as the protective value of the nail plate against trauma to the underlying distal phalanx, its counterpressure effect to the pulp important for walking and for tactile sensation, the scratching function, and the importance of fingernails for manipulation of small objects.

The nails can also provide information about the person's work, habits, and health status, as several well-known nail features are a clue to systemic diseases. Abnormal nails due to biting or onychotillomania give clues to the person's emotional/psychiatric status. Nail samples are utilized for forensic and toxicology analysis, as several substances are deposited in the nail plate

as they are produced and remain stored during growth.

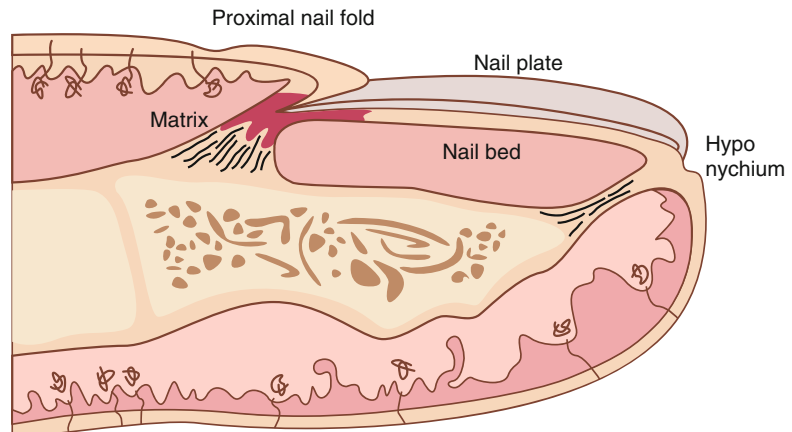
It is therefore important to know how the healthy nail appears and how it is formed, in order to detect signs of pathology and understand their pathogenesis.

1.1 Nail Anatomy and Physiology

What we call "nail" is the nail plate, the final part of the activity of 4 epithelia that proliferate and differentiate in a specific manner, in order to form and protect a healthy nail plate [1]. The "nail unit" (Fig. 1.1) is composed by:

- Nail matrix: responsible for nail plate production
- Nail folds: responsible for protection of the nail matrix

Fig. 1.1 Drawing of the nail apparatus in transverse section, showing the four structures that contribute to nail plate formation and growth: proximal nail fold, nail matrix, nail bed, and hyponychium. Note the proximity of the nail apparatus with the bone of the distal phalanx and the two ligaments that link them together



- Nail bed: responsible for nail plate adhesion during growth
- Hyponychium: responsible for nail plate detachment at the distal margin of the digit

1.2 Nail Plate

The nail plate is a fully keratinized, dead structure, which is continuously produced by the nail matrix. Nail matrix keratinocytes proliferate and undergo a sudden differentiation with loss of nuclei and strict intercellular adherence that give rise to the nail plate. The plate emerges from underneath the proximal nail fold and grows distally, surrounded by the lateral folds and adherent to the nail bed, until it detaches in correspondence to the hyponychium.

The nail plate has a rectangular shape, is semi-transparent, and has a smooth shiny surface, lined by thin longitudinal lines that increase with ageing (Fig. 1.2). It appears pink when attached to the nail bed, as it allows visualization of nail bed blood vessels, while the free edge is whitish in

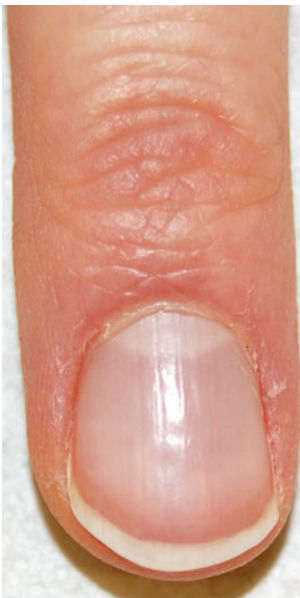

Fig. 1.2 Normal fingernail: the plate emerges from the proximal nail fold, lined by the cuticle. The plate color is pink, with a proximal oval whitish area, the lunula. The free margin is white

color. Proximally, the nail plate of fingernails and of some toenails shows a distally convex white area, the lunula, which corresponds to the distal nail matrix. The shape of the lunula determines the shape of the distal margin of the nail plate. Before the nail plate free margin, there is a transverse reddish band (the onychodermal and onychocorneal bands) that corresponds to the nail isthmus, the area of the strongest adherence between nail plate and nail bed.

The nail plate physical characteristics are unique and essential for its uses: it is hard and difficult to break, but elastic and bendable, resistant to chemicals, and strictly adherent to the underlying tissues.

These features are due to its high content in hard keratins, which constitute its 80–90 %, and to its particular anatomical structure that includes three layers:

- The dorsal part, 0.08–0.1 mm thick, consisting of tight, flattened cells, whose keratin filaments are oriented parallel and perpendicular to the growth axis. This portion gives the nail hardness and sharpness and is produced by the proximal nail matrix.
- The intermediate nail plate, 0.3–0.5 mm thick, consisting of wide and irregular cells, with keratin perpendicular to the growth axis. This portion gives the nail flexibility and elasticity.
- The ventral nail plate, 0.06–0.08 mm thick, produced by the nail bed, is necessary for the adhesion of the nail plate to the nail bed.

1.3 Nail Matrix

The matrix produces the nail plate continuously throughout life. It lies well protected under the proximal nail fold and just above the bone of the distal phalanx, to which is connected by a tendon that reaches the distal interphalangeal joint (Fig. 1.1). The strict anatomical connection between the nail unit and the distal joint explains the frequent association of fingernail and joint psoriasis (see Chap. 7).

In order to understand the anatomy of the matrix, we should look at it both in a frontal and in transverse view. In frontal view (Fig. 1.3), the matrix shows a horseshoe shape, with a distal

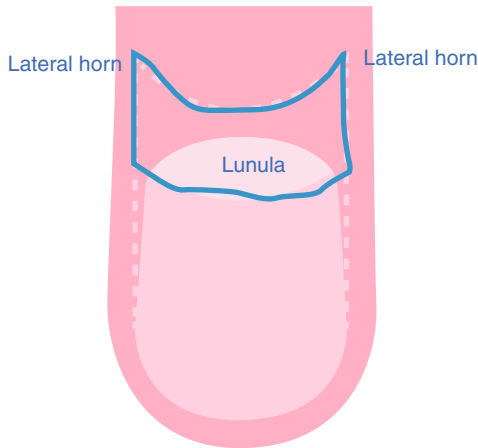


Fig. 1.3 Drawing of the matrix in frontal view: it has a horseshoe shape with distal convexity and two lateral horns

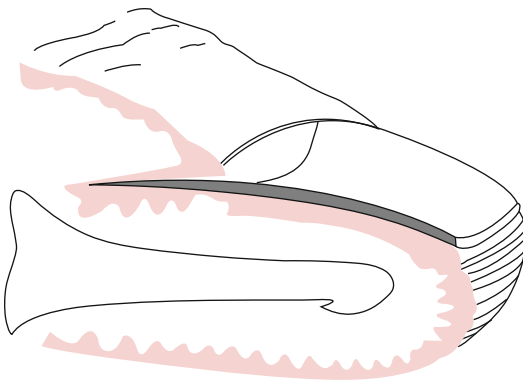


Fig. 1.4 Transverse section of the nail, showing the different epithelia. The matrix has a v-shaped appearance and distally continues with the nail bed

convexity and two lateral horns. In transverse view, the matrix has a v-shaped appearance and continues proximally with the epithelium of the proximal nail fold and distally with the nail bed (Fig. 1.4). Nail matrix keratinocytes proliferate and differentiate along an oblique axis to constitute the nail plate. Keratinization occurs abruptly, without the formation of a granular layer, corresponding to a thin eosinophilic area known as the keratogenous zone (Fig. 1.5). Matrix cells lose their nuclei and are strictly adherent to each other, with a cytoplasm completely filled by hard keratins. This gives rise to a completely transparent, flexible but hard, and resistant nail plate.

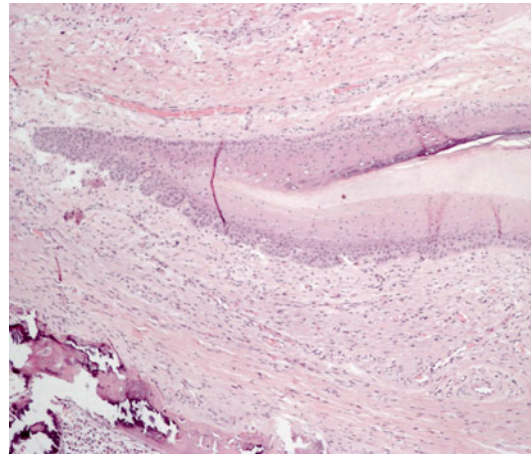
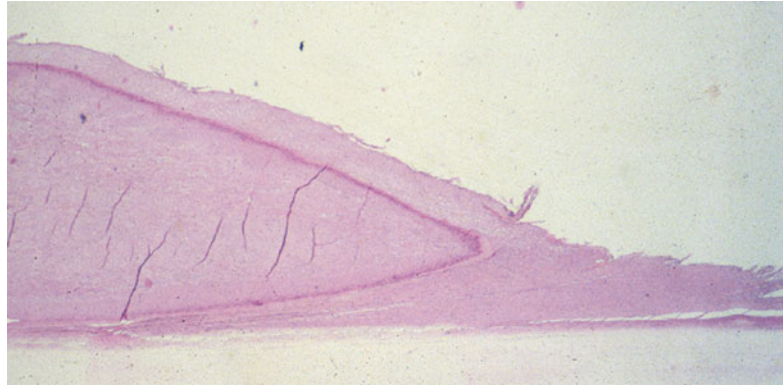

Fig. 1.5 Histopathological section of the nail matrix, showing its v-shaped appearance. The keratogenous zone appears as a eosinophilic area, above which the cells are completely transparent due to loss of nuclei. Note the bone of the distal phalanx immediately below the matrix dermis (Courtesy of Dr Cosimo Misciali)

As matrix cell keratinization and proliferation occurs along an oblique axis, the proximal matrix gives rise to the dorsal and the distal matrix to the ventral nail plate. This is very important in order to select the site of biopsy or of therapy in different nail diseases. Abnormalities of the dorsal nail plate derive from damage to the proximal nail matrix, while alterations of the ventral plate are due to damage to the distal matrix.

Beside keratinocytes, the matrix contains other cell lines, particularly melanocytes [2]. They are less numerous than in the skin and located often suprabasally and in small clusters of 3–5 cells. In Caucasians, nail matrix melanocytes do not usually produce melanin, for two reasons: (1) most of them, especially in the proximal matrix, are not activable and are DOPA negative, as they do not contain the full enzymatic equipment for melanin production; (2) the activable melanocytes, DOPA positive, present mainly in the distal matrix, are protected from UV and require strong activation before starting producing melanin. This explains why, in normal conditions, the nail plate does not have traces of melanin.

Fig. 1.6 Transverse section of the proximal nail fold, showing the cuticle, a thick horny layer adherent to the nail plate (Courtesy of Dr Cosimo Misciali)



1.4 Nail Folds

The proximal nail fold is formed by a dorsal and a ventral part: the dorsal portion continues distally with the skin of the dorsal digit, from which it differs from the absence of hair and sebaceous glands. Overlying the point of the proximal third of the distal phalanx, the skin of the proximal nail fold reflects downward and proximally and forms the ventral part of the proximal nail fold, which is not visible from the outside (Fig. 1.4) and is continuous with the nail matrix. The limit between dorsal and ventral fold is marked by the cuticle, a thin band of horny layer that seals the skin of the dorsal digit to the nail plate (Fig. 1.6), avoiding penetration of water and environmental particles under the nail fold and therefore contributing to protection of the nail matrix.

The lateral nail folds surround the nail plate, which is more or less beneath them.

1.5 Nail Bed

It has the function of allowing nail plate longitudinal growth keeping it strongly attached. For this reason, its epithelium keratinizes forming the lowest part of the plate. The nail bed dermis lies upon the distal phalangeal bone, separated from the periosteum by connective tissue, with subcutaneous fat usually absent. This explains why diseases of the nails may frequently involve the bone, as well as why bone tumors may modify the nail shape and structure. The nail bed dermis

has a unique structure, as it does not form papillae, but has dermal crests that run longitudinally, with the blood capillaries running parallel within.

The nail isthmus, which clinically corresponds to the onychodermal band, is responsible for the strong adherence between the nail plate and the nail bed and is the site of primary damage in onycholysis [3].

1.6 Hyponychium

It corresponds to the point where the nail plate detaches from the underlying tissues. Its structure resembles the skin of the pulp, with a granular layer and a thick horny layer (Fig. 1.7).

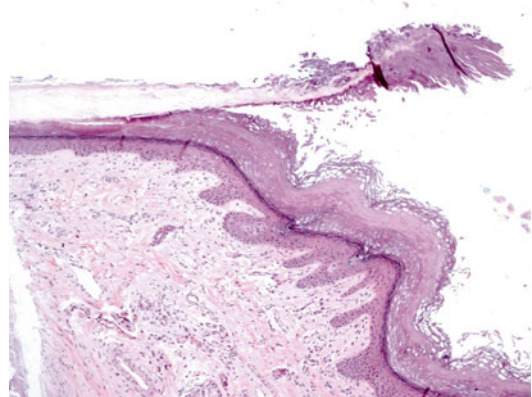


Fig. 1.7 Transverse section of the distal nail: the nail plate detaches at the hyponychium, which shows a thick horny layer produced through keratinization with a granular layer, similar to that of the plantar skin (Courtesy of Dr Cosimo Misciali)

1.7 Nail Blood Vessels

The blood capillaries of the nail unit are oriented in different ways according to location (Fig. 1.8). The capillaries of the proximal nail fold run parallel to the skin surface, in longitudinal lines with longitudinal distal loops. In normal conditions, their number is around 30 per 5 mm. They can easily be seen with a dermatoscope at 20–40× magnifications (Fig. 1.9). Alterations of number and shape of the proximal nail fold capillaries are typical of connective diseases, where they can be studied for diagnostic and follow-up purposes [4].

The capillaries of the nail matrix and the hyponychium have similarity with skin capillaries, while the capillaries of the nail bed present a unique anatomy, as they run parallel to the nail plate surface along the longitudinal crests of nail

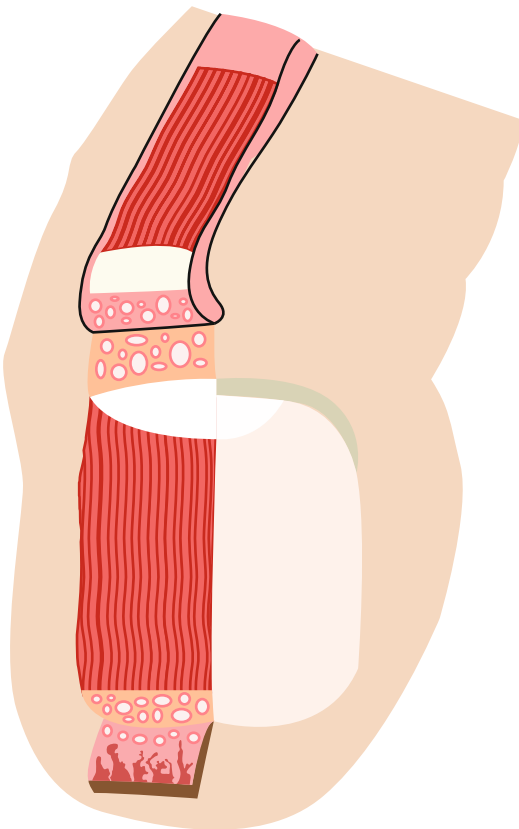


Fig. 1.8 Schematic drawing of the anatomy of nail capillaries: in the nail bed, they run longitudinally parallel to each other

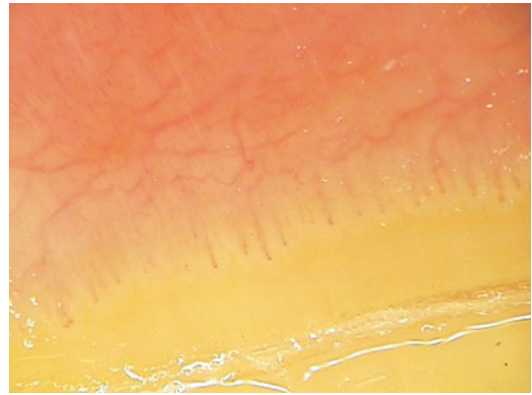


Fig. 1.9 Blood capillaries of the proximal nail fold run parallel to the skin surface and are visible with a dermatoscope




Fig. 1.10 Enlarged capillaries of the distal nail bed in a person with strong manual activity, showing their typical longitudinal shape

bed dermis (Fig. 1.10). They can be visualized in people with manual jobs and appear as small longitudinal red lines under the distal nail plate. When a capillary is damaged, the hemorrhage appears as a small black longitudinal line (splinter hemorrhage).

1.8 Nail Growth

Nail plate production and growth start during embryonic life (around the 15th week) until death.

Mean growth rate of fingernails is 3 mm/month and that of toenails is 1 mm/month. Complete regrowth of a fingernail after avulsion may require 4–6 months and up to 1 year for a toenail.

Nail growth rate is maximum in early adulthood and decreases with ageing, being influenced

by several factors, including seasonality, diseases, and drugs.

1.9 Key Points for Nail Anatomy and Physiology

1. The dorsal nail plate is produced by the proximal matrix and the ventral plate is produced by the distal matrix.
2. Even if the nail plate is not pigmented, the matrix contains melanocytes that are usually not producing melanin.
3. The cuticle has an important protective role.
4. Nail growth is slow, especially in the elderly. Thus, the growth of a normal nail after treatment may require several months.

Suggested Reading

1. Zaias N (1990) *The nail in health and diseases*, 2nd edn. Appleton & Lange, Connecticut
2. Perrin C, Michiels JF, Pisani A, Ortonne JP (1997) Anatomic distribution of melanocytes in normal nail unit: an immunohistochemical investigation. *Am J Dermatopathol* 19:462–467
3. Perrin C (2008) The 2 clinical subbands of the distal nail unit and the nail isthmus. Anatomical explanation and new physiological observations in relation to the nail growth. *Am J Dermatopathol* 30:216–221
4. Cutolo M, Sulli A, Smith V (2013) How to perform and interpret capillaroscopy. *Best Pract Res Clin Rheumatol* 27(2):237–248



本文献由“学霸图书馆-文献云下载”收集自网络，仅供学习交流使用。

学霸图书馆（www.xuebalib.com）是一个“整合众多图书馆数据库资源，提供一站式文献检索和下载服务”的24小时在线不限IP图书馆。

图书馆致力于便利、促进学习与科研，提供最强文献下载服务。

图书馆导航：

[图书馆首页](#) [文献云下载](#) [图书馆入口](#) [外文数据库大全](#) [疑难文献辅助工具](#)